



PATON & LEE

EQUINE VETERINARY SURGERY

SEASONAL MYOPATHY WARNING

Tragically, we have had two fatalities in early April due to Seasonal Pasture Myopathy (SPM) (previously known as Atypical Myopathy) caused by sycamore poisoning (due to Hypoglycin A). The cases were in horses recently turned out on the same pasture where sycamore seedlings were growing – these photographs are from the actual pasture and have been reproduced on our website and Facebook pages if you can't see them well enough here.



Recognition of this disease is relatively new to the veterinary profession, so we don't have all the answers yet, but there is a lot of current research being conducted to help our understanding. We do know that all parts of the sycamore tree are potentially dangerous, including the leaves, the helicopter seeds and the seedlings, whether alive or wilted. There seems to have been perfect climatic conditions this year to germinate a mass of seedlings within the last few weeks, so please be very careful about where your horses are turned out. The pasture where our two fatalities were turned out had been grazed by horses for many years without problems, but closer inspection revealed many sycamore seedlings, dry leaves and desiccated helicopter seeds mixed in with the grass.

Try to remove as many of the seedlings as possible by picking them by hand (wear gloves!), mowing your grazing with either a sweeper or collector behind, or spraying the paddocks. Remember, the toxin will remain in the dead seedlings - horses will need to be kept off paddocks until there is no evidence of the dead seedlings in the grazing. Diluting out the grazing with hay or other supplementary feed will reduce the quantity of sycamore ingested.

If you have sycamore seedlings in your paddocks and would like to know how potentially dangerous they are, you can send samples to the Royal Vet College who will analyse them and advise you of the concentration of Hypoglycin A within the sample. This will help to tell you how "dangerous" your paddock is. A blood sample from your horse sent to the RVC can analyse the level of Hypoglycin A in the blood – this may be useful for those horses in contact with / on the same pasture as others suffering from sycamore poisoning, but it is too soon to know if this will help with early diagnosis or prevention of the condition – this is new and ongoing research. Links to the RVC pages are on our website and Facebook page. A blood sample from your horse can be analysed at Paton and Lee for the muscle enzymes AST and CK and raised levels of these enzymes *might* indicate sub-clinical disease prompting a change in management – again, the data on this is in its infancy. We do know that in acute cases of sycamore poisoning a change in the blood AST and CK occurs AFTER clinical signs have already developed. Dark urine and other symptoms of the disease are therefore a more reliable test of poisoning.

If you would like to blood test your horse, please contact the practice on 01376 513369 during normal office hours.

Remember the laminitis risk too!

While we're warning about the seasonal risks of pasture, please don't forget that we're going into the highest risk period for laminitis too. If your horse or pony has come out of the winter in condition score 3 or over, please take care to reduce the feed you give them as the calories they consume from the growing grass increases. You should be able to easily feel your horse's ribs and see them rippling as your horse moves.



Spring-Clean Charity Collection



This April, why not make your Spring-clean go towards helping horses in the local area and around the globe? Paton and Lee are collecting bags of clean clothes and used Inkjet printer cartridges to raise much needed funds for the **Essex Horse and Pony Protection Society** and **Brooke – Action for Working Horses and Donkeys**. If you have any Inkjet printer cartridges (they're the ones with the gold dots on them – see pictures) or clothes you no longer need, hand them in at our Hoo Hall office, or give them to one of our vets when they visit. Your Spring-clean could make a huge difference to horses, ponies and donkeys that are in desperate need of help.



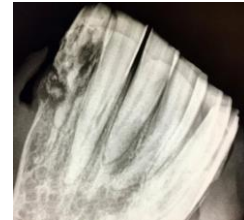
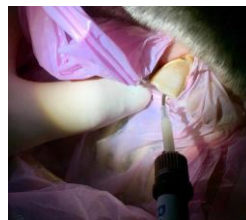
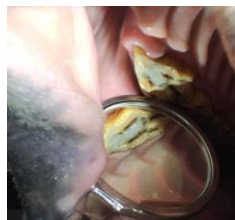
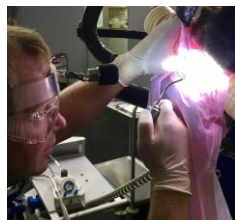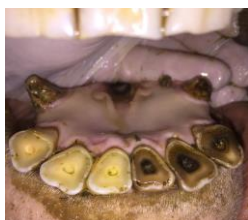Advanced Dentistry Services

Over the past decade, equine dental care has progressed rapidly and is at last catching up with that of human and small animal dentists. Paton and Lee have been constantly developing their equine dental procedures, recognising how important dental health is for horses, ponies and donkeys, and how painful dental disease can be. Horses and ponies are very good at coping with toothache and unlike with a lameness, they often don't show any obvious signs of being in chronic pain.

The vital key to good dental care is a thorough dental examination. All our vets are trained and have the equipment required to carry out proper dental examinations at your yard, but they are also able to recognise when further tests such as dental endoscopy or radiography are required to reach a diagnosis.

Paton and Lee are now able to offer more advanced equine dental treatments than ever, including:

- Foal assessments and orthodontic surgery for incisor malalignments (overbite / overjet problems).
- Diastema (gap) widening and periodontal disease treatment.
- Treatment of peripheral cemental caries (cavities).
- Simple and complex tooth extractions under standing sedation (including endoscopically guided extractions of fractured teeth, minimally invasive trephination and repulson (MITR) and minimally invasive transbuccal extractions (MTE)).
- Restoration of infundibular caries in cheek teeth (to help prevent tooth fracture and root infections).
- Restoration of incisor pulpitis and/or apical root infections (to help avoid tooth extraction).
- Surgical treatment of Equine Odontoclastic Tooth Resorption and Hypercementosis (EOTRH).



Marathon Effort

Later this month, Ben will be raising money for **Brooke – Action for Working Horses and Donkeys** by running the Virgin London Marathon ... and he'll also be dressed as a donkey! Ben's training has gone well and he's remained injury free (despite the best efforts of some of his patients!). So far, thanks to the wonderful generosity of our clients, Ben has already raised over **£2500** – so **THANK YOU** if you've already sponsored him!

It's easy to donate – just visit Ben's fundraising page at the website www.virginmoneygiving.com/ben_patonandlee or donate via the office. His fundraising goal is **£3000**, so he's almost there ... but as he's going to be making a right fool of himself in a donkey costume as well, it would be amazing if we could help smash his target, or maybe even reach **£4000!?!?**

Thank you once again!

